

PRESENTING CLINICAL SIGNS

History: Recheck degenerative valve disease. Grade 2/6 left apical systolic murmur.

DATE

12/21/21

ECHOCARDIOGRAPHIC FINDINGS

2D, M-mode, and Doppler study. This exam is compared to the one performed 6/7/21.

PERFORMED BY:

Dr. Brian Barnes

INTERPRETED BY

Keith Blass, DVM,
MS, DACVIM
(Cardiology)

Left atrial size is normal. The mitral valve leaflets are mildly thickened and exhibit systolic prolapse. A mild to moderate jet of eccentric mitral regurgitation is present. Left ventricular dimensions are normal. Left ventricular systolic function is mildly hyperdynamic. The aorta and aortic valve are normal. Right atrial and right ventricular dimensions are normal. The tricuspid valve leaflets are mildly thickened, and a mild jet of tricuspid regurgitation is present. TR velocity does not suggest the presence of pulmonary hypertension. The pulmonary artery and pulmonary valve are normal. No shunting lesions are visualized. No pericardial effusion or cardiac masses are seen.

ECG during echo: Sinus arrhythmia

PATIENT

Emmee Anderson

LA - 27.1 mm (prev. 27.5 mm)
LVIDd - 26.9 mm (prev. 26.8 mm)
LVIDs - 16.1 mm (prev. 15.0 mm)
FS - 40% (prev. 43.9%)
LVOT - 1.22 m/s (prev. 1.20 m/s)
RVOT - 0.83 m/s (prev. 0.78 m/s)
TR - 2.20 m/s (prev. 2.00 m/s)

SPECIES

Canine

ASSESSMENT/RECOMMENDATIONS

Degenerative mitral and tricuspid valve disease

BREED

JRT

This examination demonstrates no progression of Emmee's valvular diseases over the past 6 months. As such, her diseases still appear to be well-compensated, and Emma's current risk for the development of clinical signs, such as coughing, exercise intolerance, syncope, and labored breathing, appears to be low.

SEX

FS

No therapy is recommended at this stage of Emmee's valvular diseases.

A recheck echocardiogram is recommended in 6 months to monitor for disease progression.

AGE

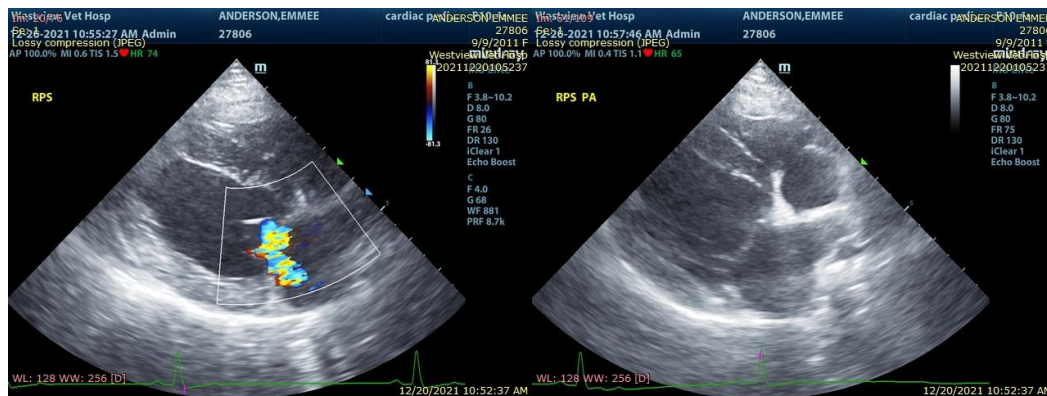
10 y

WEIGHT

7.2 kg

HOSPITAL NAME

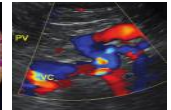
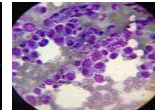
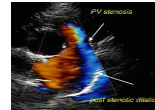
Westview VH



REFERRING VET

Dr. Barnes

The information and recommendations provided are based on the images presented by the referring veterinarian. No evaluation can be communicated regarding pathology that was not



visible in the image/video clips provided.

DATE Thank you for this referral. If the clinical or image interpretation does not parallel your findings or if I can be of any further assistance please contact me.

12/21/21

PERFORMED BY: Keith Blass, DVM, MS, DACVIM (Cardiology)
KeithBlass@gmail.com
631-804-5754

Dr. Brian Barnes

INTERPRETED BY

Keith Blass, DVM,
MS, DACVIM
(Cardiology)

PATIENT

Emmee Anderson

SPECIES

Canine

BREED

JRT

SEX

FS

AGE

10 y

WEIGHT

7.2 kg

HOSPITAL NAME

Westview VH

REFERRING VET

Dr. Barnes